

## **Intracerebral hemorrhage related to systemic gas embolism during hysteroscopy**

EMILIE GUILLARD, BÉNÉDICTE NANCY, HERVÉ FLOCH, ANNE HENCKES,  
GUY COCHARD, JOSIANE ARVIEUX, CHARLES CHRISTIAN ARVIEUX

*CHU Brest, Pôle Anesthesiology Intensive Care SAMU, Department of Anesthesiology and Intensive Care, Center for Hyperbaric Medicine, Brest, F-29200 France*

CORRESPONDING AUTHOR: Dr. Guy Cochard – [guy.cochard@chu-brest.fr](mailto:guy.cochard@chu-brest.fr)

### **ABSTRACT**

Iatrogenic gas embolism is a rare but serious problem that has been documented in almost all medical specialties including gynecology. We present a 49-year-old woman undergoing operative hysteroscopy and myomectomy, who sustained sudden hypotension and decrease in the end-tidal carbon dioxide levels during the procedure. Systemic gas embolism was confirmed by echocardiographic evidence of bubbles in both right and left cardiac cavities and a rise of troponin. Hyperbaric oxygen was rapidly administered in addition to maintenance of vital functions and anti-thrombotic prevention with calciparin. A right hemiparesis was apparent after recovery from general anesthesia. Brain-computed tomography and magnetic resonance imaging, performed on Days 3 and 2 respectively, showed a left fronto-parietal hematoma surrounded by edema. Having ruled out risk factors for a primary ischemic or hemorrhagic stroke, we concluded that hemorrhagic transformation of the ischemic cerebral lesion caused by gas embolism was responsible for the observed intraparenchymal hematoma. As far as we know, this is the first report relating cerebral gas embolism with an intracerebral hemorrhage. It provides an argument against anticoagulant therapy during the early stages of gas embolism care.

### **INTRODUCTION**

Air and gas embolism have been reported in almost all areas of clinical and surgical practice, including operative hysteroscopy (1-3). The diagnosis is not easy to establish in anesthetized patients. The direct temporal relation between the occurrence of sudden hemodynamic and/or respiratory modifications and the performance of an invasive procedure is an important clue (4). Every venous gas embolism has the potential to enter the systemic circulation and cause symptoms of end-artery obstruction.

Cerebral gas embolization is marked by edema and ischemia in multiple areas of the brain, resulting in cerebral strokes of quite variable clinical presentation. Early hyperbaric oxygen therapy (HBO<sub>2</sub>) is indicated in the presence of neurologic changes to prevent sequelae or death (5).

We present a patient who, during operative hysteroscopy and myomectomy, developed systemic gas embolism as documented by capnography and

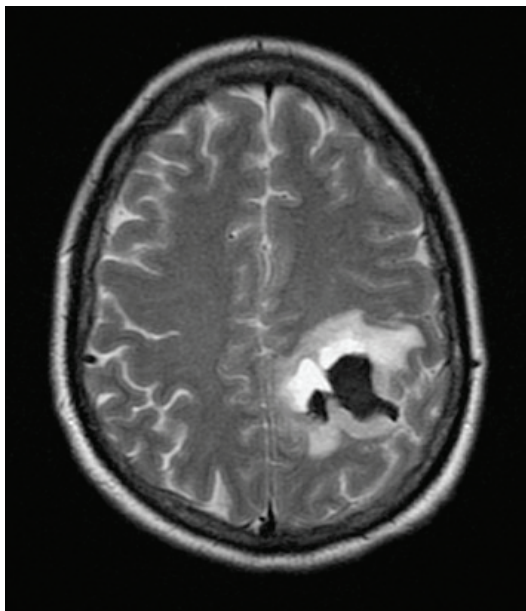
transthoracic echocardiography. Cerebral imaging studies demonstrated a single intraparenchymal hematoma, consistent with the hemorrhagic transformation of the infarcted lesion caused by arterial gas embolism.

### **CASE REPORT**

A 49-year-old, 50-kg woman, with a history of menorrhagia, was scheduled for operative hysteroscopy and myomectomy. Similar surgery was performed nine years earlier, uncomplicated. General anesthesia was induced with propofol and remifentanyl, then maintained with a combination of remifentanyl, desflurane and nitrous oxide; a laryngeal mask was inserted.

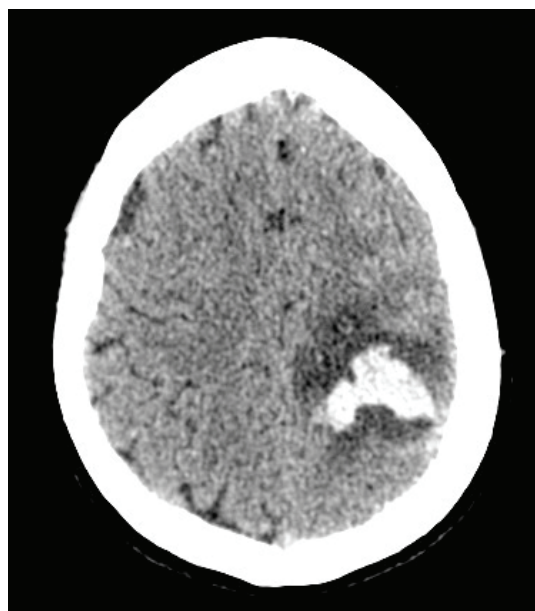
After 15 minutes of hysteroscopy under saline irrigation, a sudden hypotension and circulatory collapse occurred while end-tidal carbon dioxide (ETCO<sub>2</sub>) dropped from 31 to 17 mmHg. The patient received fluid resuscitation

**FIGURE 1**



**FIGURE 1.** MR image of recent fronto-parietal hematoma and edema surrounding the lesion on Day 2.

**FIGURE 2**



**FIGURE 2.** Cranial CT angiography showing intracranial hematoma with edema and adjacent subarachnoid hemorrhage on Day 3.

(hydroxy ethyl amidon 500 ml) and ephedrine, the trachea was intubated and mechanical ventilation was started with 100% oxygen. No immediate improvement ensued, but nor-epinephrine could finally normalize the blood pressure. No sign of anaphylactic shock was noted.

The surgery was discontinued, and a trans-thoracic echocardiography was performed shortly thereafter. Gas was visualized in the inferior vena cava and in the right ventricle with dilated right cardiac cavities. A few bubbles were also seen in the left cavities. The patient was therefore transferred to our hyperbaric center and benefited from HBO<sub>2</sub> within four hours of the embolus.

The HBO<sub>2</sub> protocol (modified from U.S. Navy tables 5A and 6A) consisted of the immediate compression to 5 ATA (40 m water depth) for 15 minutes followed by two 55-minute periods at 3 ATA and 2 ATA with 100% oxygen ventilation and gradual decompression during 30 minutes. During this initial treatment, the patient presented again with hypotension together with bradycardia that

improved by fluid infusion and increase of vasopressors.

In the intensive care unit, neurologic assessment was not feasible due to ongoing anesthesia, but the pupils remained symmetrical and reactive. Laboratory findings were normal except for a rise of troponine (3.17 ng/ml), suggesting embolization into the coronary arteries despite the lack of electrocardiographic changes or dysrhythmia. The prothrombin time was 64% with a normal aPTT. After complete warming, sedation was removed and a right hemiparesis, associated with a pyramidal syndrome, was noted. However, the patient was extubated without complication.

Because of the neurologic deficit, the HBO<sub>2</sub> treatment was continued with two more sessions the day after; treatment consisted of 100% oxygen at 2.5 ATA for 60 minutes. Antithrombotic prevention was made by two injections of 5000 IU calciparin 12 hours apart. A brain magnetic resonance imaging (MRI) was carried out on Day 2, showing a recent left fronto-parietal hematoma surrounded by ede-

ma (Figure 1, facing page). A cranial computed tomography (CT) angiography performed on Day 3 demonstrated an intraparenchymal hematoma surrounded by edema, together with a subarachnoid hemorrhage, probably due to the rupture of the hematoma (Figure 2, facing page). No vascular aneurysm, arterio-venous malformation or dural fistula was found. Supra-aortic vessels Doppler ultrasonography ruled out another etiology to this cerebral stroke. Transesophageal echocardiography showed a good left ventricular function without valvulopathy; right cavities were no longer dilated. There was no evidence of thrombus or patent foramen ovale by agitated saline contrast.

Troponine returned to normal values within four days. Thrombophilic risk factors including anti-thrombin III and antiphospholipid antibodies were not found. The TSH levels were normal, hepatitis B, hepatitis C and HIV serologies were negative. There was no additional administration of anticoagulant to prevent hematoma enlargement. Under supportive care, in the absence of indication for surgical hematoma evacuation, the patient showed gradual neurologic improvement, with mild sensitive and motor sequelae. A cerebral CT scan performed one month later demonstrated complete resorption of the hematoma with a residual hypodensity.

## **DISCUSSION**

We report the case of a patient who suffered an intracerebral hematoma as a probable consequence of gas embolism during operative hysteroscopy. Used for decades to diagnose and treat intrauterine pathologies, this procedure is considered as safe, with a short operation time in ambulatory care. It has been well-documented, however, that hysteroscopic surgery entails a risk of entry of gas into open uterine veins, which can result in serious morbidity and mortality (2, 3, 6). In such a case, gas embolism is most often air embolism, from either ambient air (which enters the uterine cavity during the insertion of the hysteroscope) or from air bubbles present in the fluid distension medium, although the highly soluble carbon dioxide used for distension or produced by electrocoagulation may also be involved (3, 6).

Whatever the source of the gas embolus, the pathophysiologic consequences are well known and the severity of injury depends on the volume and the rate of gas insufflation into veins (1). Rapid entry of large volumes of gas that obstruct the pulmonary circulation put a strain on the right ventricle through an increase of the pulmonary arterial pressure and may cause cardiovascular collapse by reducing left ventricular preload (4).

Another risk exists in that gas bubbles may cross to the systemic circulation either through a right-to-left intracardiac shunt (e.g., a patent foramen ovale) and/or through the pulmonary vasculature (7). Such a paradoxical embolism was proved by the detection of bubbles in both right and left cardiac cavities in the case reported here.

As for previous isolated observations of cerebral ischemia caused by venous gas embolism, no intracardiac defect or shunt could be demonstrated in our patient (4, 8). In these situations, it should be assumed that the ability of the lungs to filter out gas emboli is exceeded. For example, in dogs a transpulmonary passage of venous air emboli with arterial spillover was demonstrated above a critical rate of infusion of 0.3 ml/kg/min (9). Moreover, various anesthetic agents have been shown to alter the filtration of venous gas emboli by the pulmonary vasculature, a finding possibly relevant to the present observation (4). Also, the opening of dormant or anatomical intrapulmonary arteriovenous shunts may have occurred with the increase of pulmonary arterial pressure (1, 4).

Because early detection of gas embolism and adequate intervention are crucial for survival, any sudden neurological and/or cardiorespiratory sign during an invasive procedure carrying a risk of venous or arterial gas embolism should lead to consideration of this diagnosis (4). In our anesthetized patient monitored by capnography, gas embolism was suspected on the otherwise-unexplained and sudden fall in both blood pressure and  $ETCO_2$  (due to lung regions with high ventilation/perfusion ratios). To confirm the diagnosis, the most specific and sensitive means for precisely locating intracardiac gas are immediate precordial Doppler ultra-

sonography or transesophageal echocardiography, the latter allowing to detect air bubbles as small as 5-10  $\mu\text{m}$  (7). Non-contrast brain CT, performed early (within a few hours of symptom onset), sometimes reveals single or multiple air-isodense spots within one or both hemispheres – highly suggestive of cerebral air embolism; however, its normality does not exclude the diagnosis (1, 4, 8). Delayed CT scans may show low-density lesions of varying sizes consistent with infarction. In the present case, a focal neurologic deficit was apparent after the patient recovered from the anesthesia; cerebral imaging was performed on Days 2 and 3, for MR and CT respectively, which surprisingly showed an intraparenchymal hematoma.

Cerebral gas embolization typically causes:

- (i) a mechanical obstruction of small arteries; and
- (ii) an inflammatory response to the bubbles responsible for edema (both vasogenic and cytotoxic), local ischemia and infarction with lesions of the adjacent hematoencephalic barrier (1, 4).

This is reminiscent of the pathologic changes described in acute thromboembolic stroke. Hemorrhagic transformation is a natural consequence of cerebral infarction, occurring more frequently after embolic stroke than after thrombotic events. For example, in patients with acute cerebral embolism examined with serial CT and angiography, secondary hemorrhage during the month after the stroke reached 40.6%, in relation with reopening of the occluded vessels and the size of the infarct (10).

In our patient, risk factors for stroke such as hypertension, cerebral vascular malformation, cardiopathy, carotid arteriosclerosis, coagulation abnormality or diabetes were absent; this makes unlikely the occurrence of a primary ischemic or hemorrhagic stroke. Instead, we believe that hemorrhagic transformation of the ischemic cerebral lesion caused by gas embolism was responsible for the observed hematoma. To the best of our knowledge, this is the first report

relating cerebral gas embolism to an intracranial hemorrhagic lesion.

This observation may illustrate the danger of early anticoagulant therapy with heparin, although there is some experimental evidence that heparin may be beneficial by reducing neurological impairment after cerebral air embolism (11). Indeed, heparin therapy in the acute phase of cerebral embolism entails a risk of massive hemorrhage into the infarcted tissue, especially in the elderly and in patients with large infarcts (10, 12). At present, its use is not generally recommended in this setting (4).

HBO<sub>2</sub> is the first-line treatment of choice for arterial gas embolism (primary or paradoxical), being applied as soon as possible and best within six hours of the accident (5, 13). This therapy decreases the size of the gas bubbles both by raising the ambient pressure and by causing systemic hyperoxia. Also, it may help prevent cerebral edema and reduce the adherence of leukocytes to damaged endothelium (4). Regarding intracranial hemorrhage, no adverse effect is to be expected from HBO<sub>2</sub>. On the contrary, early HBO<sub>2</sub> treatment has been reported to induce attenuation of hemorrhagic transformation in a rat model of focal cerebral ischemia (14). Between HBO<sub>2</sub> sessions, a normobaric oxygenation is recommended (1). In addition, the infusion of colloid solutions is accepted treatment to achieve normovolemia and thus optimize the microcirculation (4).



## REFERENCES

1. Souday V, Asfar P, Muth CM. Prise en charge diagnostique et thérapeutique des embolies gazeuses. *Réanimation* 2003; 12:482-490.
2. Grove JJ, Shinaman RC, Drover DR. Noncardiogenic pulmonary edema and venous air embolus as complications of operative hysteroscopy. *J Clin Anesth* 2004; 16:48-50.
3. Imasogie N, Crago R, Leyland NA, Chung F. Probable gas embolism during operative hysteroscopy caused by products of combustion. *Can J Anaesth* 2002; 49:1044-1047.
4. Muth C M, Shank ES. Gas embolism. *N Engl J Med* 2000; 342:476-482.
5. Blanc P, Boussuges A, Henriette K, Sainty JM, Deleflie M. Iatrogenic cerebral air embolism: importance of an early hyperbaric oxygenation. *Intensive Care Med* 2002; 28:559-563.
6. Groenman FA, Petrers LW, Rademaker BM, Bakkum EA. Embolism of air and gas in hysteroscopic procedures : pathophysiology and implication for daily practice. *J Minim Invasive Gynecol* 2008; 15: 241-247.
7. Thackray NM, Murphy PM, McLean RF, DeLacy JL. Venous air embolism accompanied by echocardiographic evidence of transpulmonary air passage. *Crit Care Med* 1996; 24:359-361.
8. Jensen ME, Lipper MH. CT in iatrogenic cerebral air embolism. *Am J Neuroradiol* 1986; 7:823-827.
9. Butler BD, Hills BA. Transpulmonary passage of venous air emboli. *J Appl Physiol* 1985; 59:543-547.
10. Okada Y, Yamaguchi T, Minematsu K et al. Hemorrhagic transformation in cerebral embolism. *Stroke* 1989; 20:598-603.
11. Ryu KH, Hindman BJ, Reasoner DK, Dexter F. Heparin reduces neurological impairment after cerebral arterial air embolism in the rabbit. *Stroke* 1996; 27:303-310.
12. Babikian VL, Kase CS, Pessin MS, Norrving B, Gorelick PB. Intracerebral hemorrhage in stroke patients anticoagulated with heparin. *Stroke* 1989; 20:1500-1503.
13. Benson J, Adkinson C, Collier R. Hyperbaric oxygen therapy of iatrogenic cerebral arterial gas embolism. *Undersea Hyper Med* 2003; 30:117-126.
14. Qin Z, Karabiyikoglu M et al. Hyperbaric oxygen-induced attenuation of hemorrhagic transformation after experimental focal transient cerebral ischemia. *Stroke* 2007; 38:1362-1367. □